

MR TRACKABLE, CHEMOTHERAPEUTIC NANOPARTICLES FOR PATIENT SPECIFIC GLIOMA THERAPY

E. Karathanasis*, K. McNeeley*, A. Agarwal*, A.V. Annapragada**, and R.V. Bellamkonda*

* Wallace H Coulter Department of Biomedical Engineering, Georgia Tech/Emory University, Atlanta, GA 30332

** School of Health Informatics, University of Texas, Houston, TX 77030

Current approaches for the treatment of glioma are limited in their effectiveness because malignant brain tumors are characteristically diffuse, highly invasive, and non-localized. Upon diagnosis of malignant gliomas, complete surgical resection of gliomas is a rarity. Following surgery, radiation has poor results while chemotherapy has been minimally effective. The success of chemotherapeutic agent therapy for intracranial tumors is critically dependent on the access that these agents have to tumors even with the so-called leaky vasculature across the blood-brain barrier. Systemic delivery of long circulating liposomal nanocarriers has exhibited increased chemotherapeutic drug delivery to solid tumors [1] due to the combination of prolonged circulation in blood and preferential accumulation in solid tumors by passive convective transport through leaky endothelium [2].

Unfortunately, the outcome measures used in many laboratories including ours is typically survival of animals after nano-carrier mediated chemotherapy. However, there exist no tools currently to rationally determine whether tumor blood vessels at a given tumor stage are amenable to nanocarrier mediated therapy in an individualized, patient specific manner today. Such a determination would no doubt be of great benefit for the planning and assessment of multiple chemotherapeutic strategies, including one used in this study. For instance, non-invasive tumor vessel angiography and tumor vessel leakiness would enable the assessment of the probability of success of chemotherapeutic agents, and would also enable determining the optimal times of chemotherapy administration. One recent example demonstrating the critical role that tumor vessels play in determining therapeutic outcomes comes from the work of Jain et al, where they demonstrate the modulation of tumor vessels by normalizing them leads to better chemotherapeutic outcomes [3].

Recent studies in our lab investigated the therapeutic effect of Stealth[®] liposome encapsulating doxorubicin (chemotherapeutic) for the treatment of glioma in a rat brain tumor model by using the survival time as an evaluation tool (Fig. 1.A). The data show a statistically significant increase in survival time for the treatment when compared to a saline sham injection. However, in such studies it is difficult to optimize the therapy protocol with respect to type of systemic chemotherapy, dosimetry and dose frequency.

To address the need to “interrogate” tumor status and non-invasively track chemotherapy, we have developed a novel nanoscale, long-circulating liposomal carrier capable of carrying contrast agents for contrast enhanced MR angiography as well as chemotherapeutics. Conventional MR contrast agents restrict the time window for image acquisition due to their rapid elimination from blood and their rapid diffusion into the extravascular space, which results in low signal to noise ratio. Our nanoscale particle consists of a Pegylated liposome with sizes of either 50 or 100 nm, encapsulating Gd-DTPA (MR agent) and/or doxorubicin (chemotherapeutic). The long circulation allowed

enhanced signal for long scanning times resulting in high resolution MR images of rat vasculature [4,5]. In this work, we have validated the utility of our nanoscale contrast agent in 9L glioma model rat using a 9.4 Tesla Bruker Biospin MR system.

The changes in blood T2 relaxation time were measured ex vivo in the 9.4T MR system. Upon injection of the nanoparticle, a sharp decrease in the blood T2 from the pre-injection value of 120 ms to the post-injection value of 18 ms after 5 min was observed which was maintained for at least 3hrs. This produced high resolution (78 μ) MR angiography images (Fig. 1.B) allowing clear visualization of the healthy brain blood vessels as well as the details of the cancerous lesion. Histological analysis (Fig. 1.B inset) verified the MR findings. The liposome distribution within the tumor lesion was obtained by scanning at t=48hrs after injection allowing enough time for maximum extravasation to occur as well as clearance of the particles from the blood pool. Indeed, the signal from the blood pool was eliminated at t=48hrs. The regional distribution of Gd-liposomes observed in the MR images was verified by histological analysis. Such a strategy would allow the non-invasive tracking of the fate of a systemically-administered nanoparticle and would potentially lead to more rationally optimized protocols for nanocarrier mediated glioma therapy.

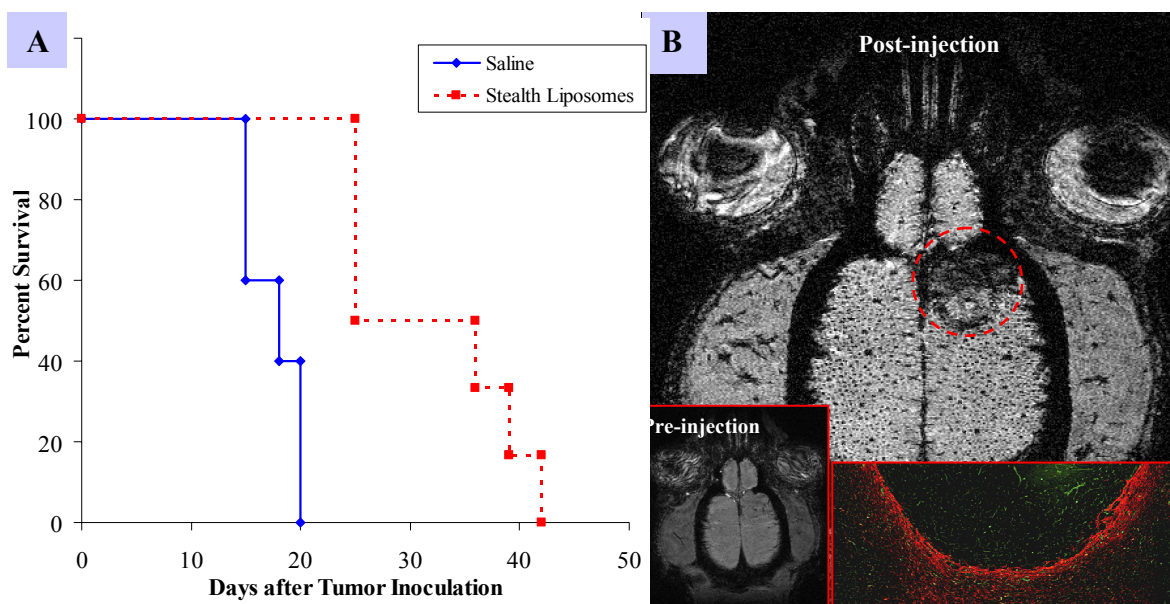


Figure 1. (A) Survival of Fisher 344 rats with 9L glioma tumor in response to liposome treatments and **(B)** post-contrast agent MR angiography; Bottom left: pre-contrast agent MR angiography; Bottom right: Microscopical view (20x) of a frozen section of the tumor lesion. Astrocytes and blood vessels are seen in red and green respectively.

REFERENCES

1. A. Gabizon et al., *Clin. Pharmacokinet.* 42(5) (2003) 419.
2. H. Maeda et al., *Adv. Drug Deliv. Rev.* 46 (2001) 169.
3. R.K. Jain et al., *Science* 307 (2005) 58
4. A.L. Ayyagari et al., *Magnetic Resonance in Medicine* 55 (2006) 1023
5. K.B. Ghaghada et al., *American Journal of Neuroradiology* 28 (2007) 48
6. The financial support from National Science Foundation (RVB) is gratefully acknowledged.